

Jon R. Wagner, DDS

A 3¹/₂-year Clinical Evaluation of Resorbable Hydroxylapatite OsteoGen[®] (HA Resorb)[®] Used for Sinus Lift Augmentations in Conjunction with the Insertion of Endosseous Implants

Abstract

A clinical study is presented of two cases in which resorbable hydroxylapatite [OsteoGen[®](HA Resorb)[®]], was used for sinus augmentation and sinus floor elevations. The insertion of endosseous titanium implants was done at the time of the sinus elevations.

Introduction

Dental diseases leading to the destruction and loss of the natural dentition and supporting structures have always created serious restorative problems for dentistry. Esthetic and functional compromises were frequently necessary because of a lack of sufficient bone. In the past decade, considerable advances have been made toward reconciliation of this age-old problem, whether in reconstructing an edentulous patient with a fully-implant-supported prosthesis, coating implants with hydroxylapatite, repairing maxillofacial defects, elevating and augmenting a maxillary sinus, treating periodontal infra-bony pockets, or even repairing an unesthetic alveolar defect under the pontics of a conventional fixed bridge.

The maxillary posterior alveolar ridge has been particularly problematic as a site for dental implants, largely due to the presence of the maxillary sinus. In addition to the usual post-extraction atrophic changes that occur in other areas of both alveolar ridges, the maxillary posterior ridge

undergoes an even greater degree of atrophy as a result of the effects of the maxillary sinuses.

The sinuses serve as air chambers, functioning as a means to remove foreign matter from inhaled air by virtue of a ciliated epithelial lining. They act as a warming chamber to pre-heat chilled air before allowing it to be passed into the bronchi and lungs. They create a resonance chamber to contribute to modulation of vocal expression. Since the ostium, or antral opening to the naso-tracheal pathway, is quite small relative to the sinus volume, a slight positive intra-sinus pressure can enlarge the volume of the antrum. This enlargement is exacerbated by early tooth loss and usually is at the expense of the alveolar ridge; it is frequently referred to as sinus or antral pneumatization. The periosteum of the Schneiderian membrane exhibits an increase in osteoclastic activity, resulting in resorption of the sinus floor after tooth loss (Linkow, 1979). These changes result in an overall reduction in the quantity as well as quality of bone in the posterior portion of the maxillary alveolar ridge. This additional bone loss can adversely af-

fect the predictability of endosseous implants placed in these host sites unless corrective intervention is instituted.

The use of hydroxylapatite alloplastic materials is well-known in oral implantology. Largely through the efforts of Jarcho *et al.* (1976) in the United States and dePutter and co-workers (1983) in Europe, the potential of hydroxylapatite ceramics as bone grafts in dentistry has been developed to the state leading to their commercial availability over the last decade. Sintered ceramic and non-sintered non-ceramic hydroxylapatite have been utilized extensively as alloplastic materials in recent years. The rationale for the use of hydroxylapatite is based on the fact that the inorganic phase of bone and teeth is an apatitic calcium phosphate (Judy, 1986; LeGeros, 1988; Jarcho *et al.*, 1976; Lemons, 1985; McKinney and Lemons, 1985; dePutter *et al.*, 1983; Brown *et al.*, 1987). However, there are differences in some of the physicochemical properties of biological apatites and hydroxylapatite ceramics. Some of the differences, including the presence of bone growth factors in autogenous bone, may explain the greater success observed with autogenous bone compared with sintered non-resorbable hydroxylapatite (HA) ceramic (LeGeros, 1988; Jarcho *et al.*, 1976). Even so, it should be recognized that there were several decided advantages in the use of non-resorbable hydroxylapatite (HA) materials as compared with autogenous bone, as listed in the Table (Laskin, 1982, as reprinted in LeGeros, 1988).

However, the non-resorbable, sintered ceramic types of hydroxylapatite (HA) alloplastic materials which have been utilized most frequently have proved to be deficient in fulfilling the requirements necessary to provide successful host sites for the placement of osseointegrated endosseous implants. The non-resorbable forms of hydroxylapatite have not demonstrated the capability to initiate osteoconductive or osteoinductive bone development successfully, as postulated by some of the earlier research studies and promoted by some manufacturers (Wagner, 1989, 1990). Rather than resulting in formation of new bone through osteoconductive or -inductive mechanisms, as experienced with allografts and autogenous grafts, the non-resorbable HA materials become encapsulated with a matrix of dense fibrous connective tissue (Hubbard, 1974). As a host site for endosseous implants, non-resorbable augmented areas can afford fibro-elastic attachment only at the host-implant interface. The potential for a direct bone-to-implant interface, or osseointegration, does not occur with these materials.

In more than 500 applications, this author has used resorbable hydroxylapatite [OsteoGen® (HA

Resorb)® Impladent LTD., Holliswood, NY) (RHA) for the repair of osseous defects, craters, apicoectomies, sinus elevation augmentations, and in conjunction with most routine endosseous implant surgical cases (Wagner, 1989, 1990). Histologic evaluations of four-month and 14-month graft entry specimens showed the osteoconductive capacity of the resorbable material to aid in the formation of new bone of high density without the typical fibrous encapsulation usually seen with sintered ceramic non-resorbable hydroxylapatite (LeGeros, 1988; Jarcho *et al.*, 1976; Chanavaz, 1990; Linkow, 1986; Cranin *et al.*, 1987).

Of the two cases presented, both were restored by simultaneous implant placement at the time of the sinus augmentations using resorbable hydroxylapatite. Resorbable hydroxylapatite (RHA), β -tricalcium phosphate, autogenous bone, and freeze-dried demineralized bone have been used successfully to correct bone deficiencies to improve potential host sites for endosseous implants (Linkow, 1979; Whittaker and James, 1989). The maxillae and mandibles were restored with titanium blade- and root-form implants. After healing, the implants provided the prosthetic abutments for upper and lower full-arch porcelain veneer bridges. Two different methods of sinus augmentation were used—one conservative, the other more complex.

Materials

OsteoGen® (HA Resorb)® is a pure, uniquely resorbable hydroxylapatite (RHA) implant material used for alloplastic augmentation and repair of bone defects. The material is physiochemically and crystallographically equivalent to the mineral portion of human bone, specifically, $\text{Ca}_{10}(\text{PO}_4)_6(\text{OH}_2)$ (Hubbard, 1974; Jarcho *et al.*, 1976).

Density, crystal size, and porosity determine the resorbability of hydroxylapatite (HA) alloplastic implant materials. Densely sintered pure hydroxylapatite ceramic materials have low microporosity, high density, and are prepared in relatively large particle sizes (from 18 to 40 mesh) in most commercially available alloplastic preparations, being subjected to very slow resorption rates

TABLE
CHARACTERISTICS OF AN IDEAL BONE GRAFT

Non-toxic	Strong
Non-antigenic	Resilient
Non-carcinogenic	Easily fabricated
Does not cause resorption	Readily available
Resistant to infection	Inexpensive
Facilitates tissue attachment	Easily adaptable to fit individual variations

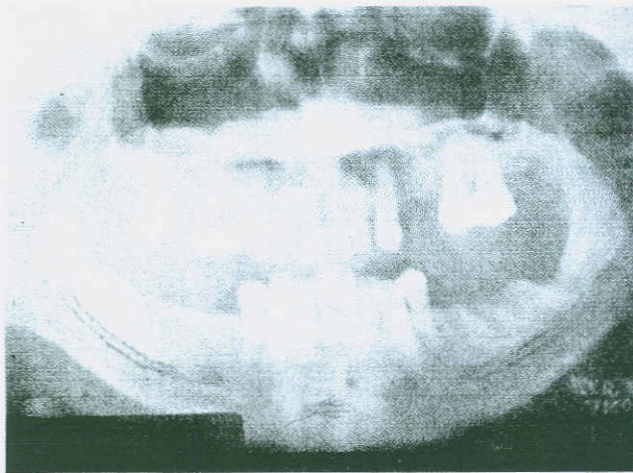


Figure 1. Case 1. Pre-operative panorex.

(Jarcho *et al.*, 1976; Chanavaz, 1990). Conversely, resorbable hydroxylapatite (RHA) is a highly micro-porous, non-sintered (non-ceramic) material composed of small crystals of 300–400 microns (35–60) mesh, with a controlled, predictable rate of resorption in most batches (Wagner, 1989, 1990; LeGeros, 1988).

As non-sintered (resorbable) hydroxylapatite (RHA) resorbs, it acts as a mineral reservoir and contributes to new bone formation *via* osteoconductive mechanisms. This "mineral reservoir" concept has been demonstrated by numerous animal and human histologic studies which strongly suggest a direct correlation of increasing bone density and maturation with an on-going reduction in the mass of refractile crystalline particles of RHA as a function of time (Wagner, 1989, 1990; LeGeros, 1988; Spivak *et al.*, 1990).

A hemostatic microfibrillar collagen, Avitene® (MedChem Products, Inc., Houston, TX) is used with the resorbable hydroxylapatite (RHA), OsteoGen® (HA Resorb)®. A one-to-five ratio, by volume, of the microfibrillar collagen hemostat is mixed with the resorbable hydroxylapatite and freshly drawn venous blood. The mixture requires only a small amount of the microfibrillar collagen for hemostasis to be produced. These materials are mixed in a sterile porcelain Petri dish to a thick putty-like consistency prior to placement. Excess serum is absorbed by being blotted with a sterile surgical 2 × 2 sponge so that a more firm consistency of the mixture can be obtained. Although hydroxylapatite products are non-inflammatory and biocompatible, collagen products can cause allergic inflammatory reactions, and a patch test should be performed prior to surgery, especially on patients who have numerous allergies (Wagner, 1989; Wicher, 1975; Feigel, 1989).

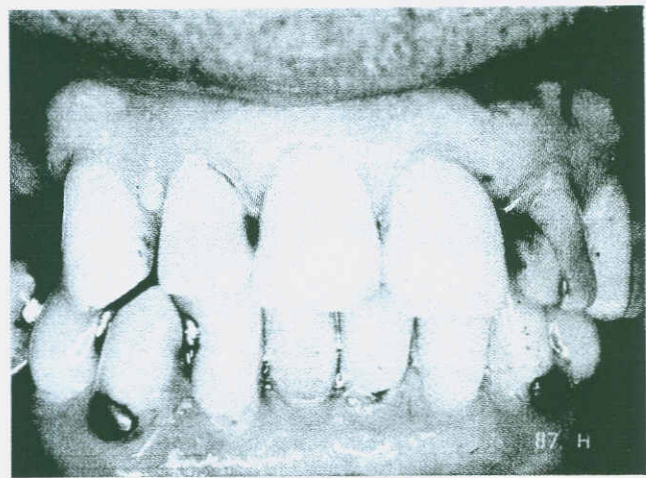


Figure 2. Case 1. Pre-operative clinical view.

The pure titanium endosseous implants used in these cases were Ultimatics, Linkow Blade Implants (Springdale, AR). The mandibular implant designs have fixed transmucosal prosthetic bendable abutments, while the maxillary models shown are submersible with removable abutments and healing collars.

Case 1

A fifty-six-year-old male presented for an examination in good general health. The radiographic and clinical survey revealed advanced periodontal disease with Class II to Class III mobility of the majority of his remaining teeth. In the maxillae, 11 teeth were present: the six anterior teeth, the right 1st and 2nd premolars, both 2nd molars, and the left 1st molar. The maxillary premolars, molars, and the left lateral incisor defied periodontal treatment. In the mandible, six anterior teeth (both 1st and the right 2nd premolars and 1st and 3rd molars) remained. All were periodontally mobile, with only a few millimeters of bone remaining (Figs. 1, 2).

After the findings from the clinical and radiographic examinations were reviewed, a treatment plan was proposed for the extraction of all the remaining mandibular teeth and the maxillary premolars, molars, and the left lateral incisor. Through the utilization of resorbable hydroxylapatite grafts to fill alveoli and to repair cortical fenestrations and defects after the extractions, the alveolar ridge height and architecture were to be restored, thus enhancing the site for the placement of endosseous implants.

After hematologic and physical evaluation of the patient's medical status, antibiotic and nutri-

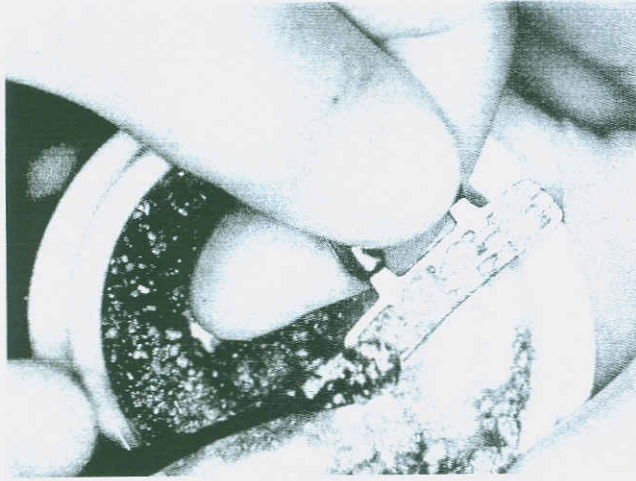


Figure 3. Coagulum of resorbable RHA OsteoGen is grouted to fill the vents in the body of the blade implant.

tional therapy procedures were initiated prior to surgery.

Extractions, alveoplasty, and grafts

The patient was pre-medicated with 2 mg of fluorazepam the evening before surgery and 1 mg 45 min before surgery. 75 mg of meperidine for conscious sedation and 8 mg of dexamethasone for the control of post-operative edema were administered intra-muscularly just prior to surgery. The patient was prepared and draped in the usual manner, and a Betadine extra- and intra-oral scrub was performed. Vital signs were monitored throughout the procedure. Bilateral inferior alveolar blocks and local infiltration anesthesia were administered with bupivacaine.

All of the maxillary and mandibular posterior teeth were extracted and the sockets and defects curetted and decorticated. A conservative alveoplasty was performed, and all sockets and bony irregularities were filled with a coagulum of resorbable hydroxylapatite (Avitene), freshly drawn autogenous venous blood, and 75 mg of tetracycline. Immediately after closure, maxillary and mandibular temporary partial dentures were inserted. Surgical insertion of full-arch mandibular endosseous implants and the extraction of the remaining six lower anterior teeth were planned after the posterior grafts were allowed to heal for three months in the mandible and four months in the maxillae.

Maxillary implant surgery

Maxillary extractions with RHA grafts and periodontal therapy were completed. This was followed by conservative sinus elevation procedures, which

were performed bilaterally. It was planned to insert two submersible blade implants (Ultimatics) concomitantly (Linkow, 1986; Feigel, 1989).

The patient was prepared, draped, and anesthetized in the usual manner. The same drug regimen as described for the first surgery was instituted with the addition of a sinus decongestant, phenylpropranolamine HCl (Ornade), beginning 24 h preoperatively. Bilateral incisions were made from the distal area of the maxillary tuberosity to the canine area just palatal to the alveolar crest, with facial vertical relief incisions at the canine eminences. Full-thickness flaps were reflected both palatally and facially, exposing the entire posterior alveolar ridges. This facilitated direct visual observation and avoided undercut areas. Osteotomies, three centimeters in length, were prepared by use of Perimatrix internally irrigated circular bone saws in a low-speed (300–400 RPM) R.A., high-torque hand-piece, and 700XL surgical burs extending bilaterally from the maxillary tuberosities to the canine eminences. These posterior osteotomies were created perpendicular to the floor of the maxillary sinuses for the purpose of elevating the sinuses bilaterally. Sinus-lift procedures were performed bilaterally by limiting the osteotomies' depths to the cortical plates of the antral floor, 4–5 mm in the first molar area, and extending the osseous incisions 8–10 mm into the deeper bone of the pre-sinus and tuberosity areas, mesially and distally adjacent to the low sinuses. In these areas adequate bone depth was available to allow the full depth of both ends of the 28-mm-long blade implants to be firmly seated 2 mm beneath the crest of the alveolar ridge without violation of the antral floor (Linkow, 1979; Feigel, 1989). The resorbable hydroxylapatite coagulum was prepared to a thick-putty consistency and grouted into the open vents of the blade implants (Fig. 3). A portion of the prepared graft was also introduced into the osteotomy to fill approximately 4 mm of the middle section of the channel located directly beneath the antral floor's cortical plate prior to insertion of the implants. The grouted blade implants were then introduced into the osteotomies and carefully tapped into a partially seated position. Periapical radiographs were taken to verify optimal positioning prior to final seating of the implants. With the graft material sandwiched and compressed between the implant and the cortical plate of the antral floor, a controlled but sharp series of taps was made carefully with the titanium seating instrument to cause a green-stick fracture and elevation of the antral floor without perforation or laceration of the Schneiderian membrane, which permitted the implants to become seated fully (Fig. 4A). At this point, the mesial and distal portions of the blade im-

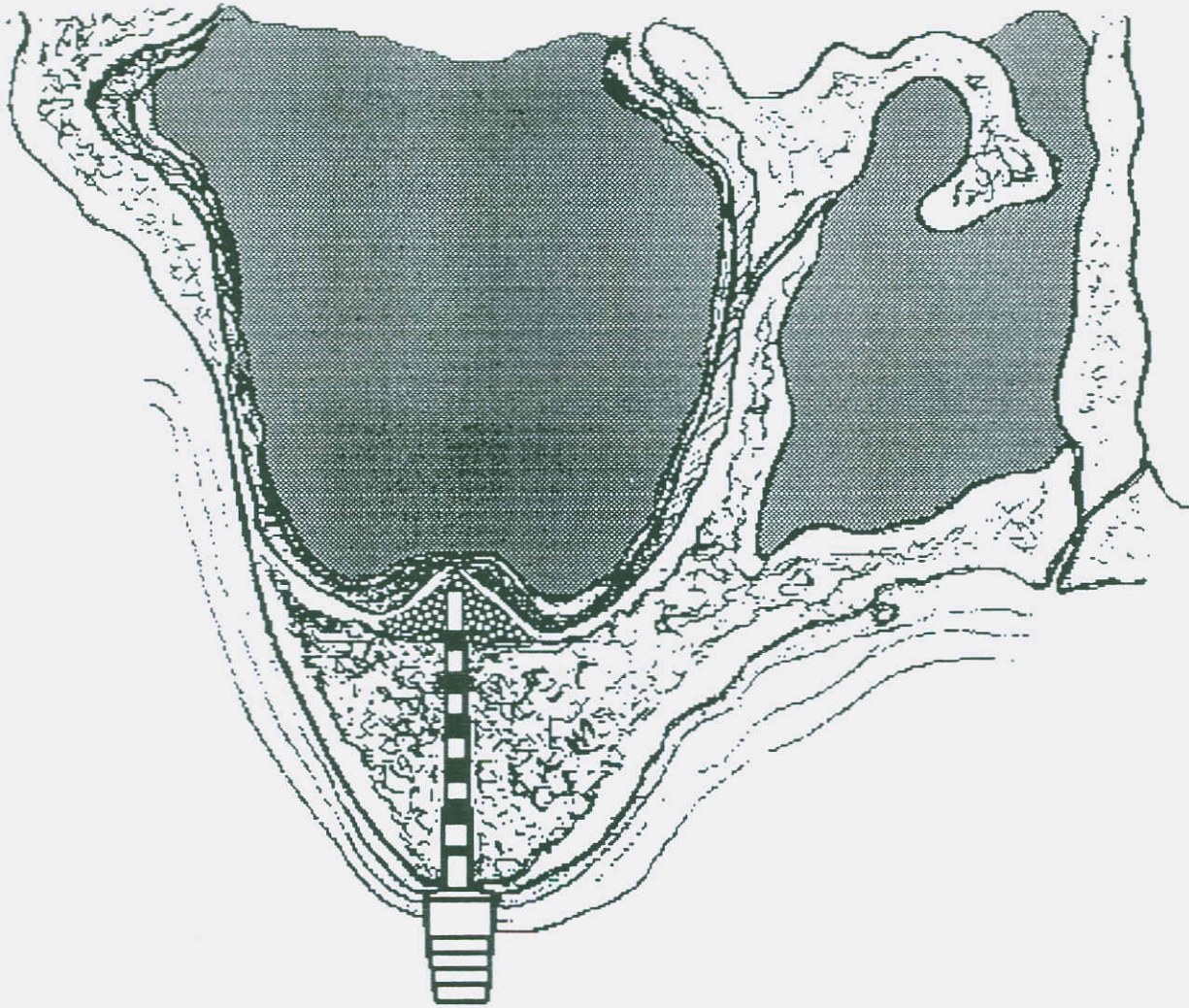


Figure 4a. Diagram of cross-section of maxillary sinus with conservative sinus floor "green stick" fracture and 2-4-mm elevation of Schneiderian membrane with base of a blade implant seated to cortical bone of sinus floor and malletted to fully seated position.

plants were securely seated in their respective positions in the osteotomies, with limited depth of penetration into the sinuses. The bases of the abutments rested in contact with the alveolar crest with the shoulders of the implants 2 mm into the osteotomies. The implant osteotomies were filled level with the ridge crest with the RHA coagulum to cover the implant shoulders (Fig. 4b). An overlay graft of non-resorbable HA (Osteograf, CeraMed, Lakewood, CO), prepared in the same manner as the resorbable material, was placed over the entire buccal and crestal surfaces to an average thickness of two mm.

Mucoperiosteal flap borders were co-apted and closure made with 3/0 chromic gut sutures. Frequent irrigation and lavage of the surgical sites

with sterile, normal saline was performed throughout the procedure so that tissue hydration would be maintained. Healing was uncomplicated and uneventful.

After a period of four months, the submerged implant necks were surgically exposed, abutments affixed, and the prosthetic phase completed by fabrication of a full-arch porcelain veneer bridge (Figs. 5 & 6a, b).

Discussion: Case 1

The healthy Schneiderian membrane is somewhat resilient and slightly elastic, with a periosteal attachment to the cortical bone of the antral floor that allows it to separate easily and cause bleeding into the void created by the tent-like elevation of

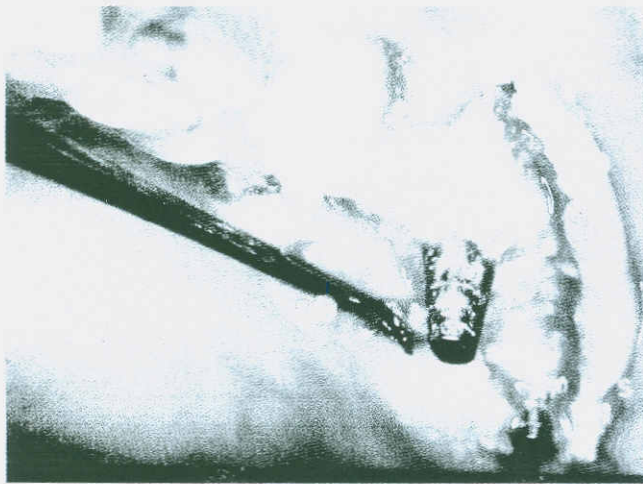


Figure 4b. After the implant is seated, the osteotomy is grouted over the shoulders of the implant, and a non-resorbable mixture is overlaid to add bulk to the ridge to enhance pontic adaptation and help prevent tissue invagination.

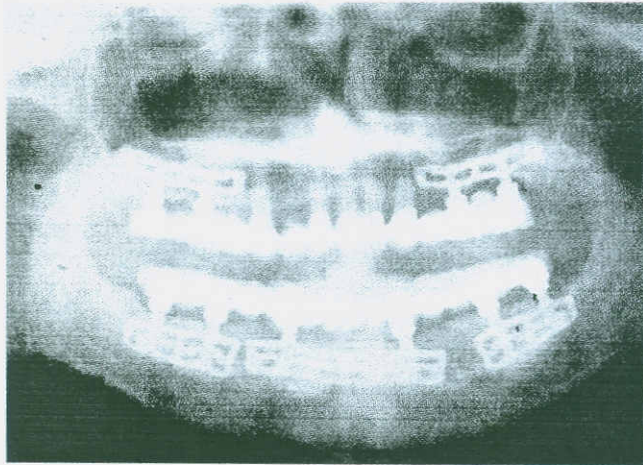


Figure 5. A post-operative panorex of completed case.

the membrane. Clot formation and organization occur around the titanium implant and adjacent bone (Misch, 1987). It is theorized that some of the graft material grouted into the implant fenestrations and sandwiched between the base of the implant and antral floor will disperse beneath the membrane, aiding in osteoconductive formation of new bone to form an elevated sinus floor and create osseointegration. The blood supply is provided to the sinus augmentation grafts by the antral periosteum as well as by the cancellous bone of the alveolar ridge. The non-resorbable hydroxylapatite (HA) Osteograft (CeraMed, Lakewood, CO) (Fig. 4b) was added to Avitene, and venous blood was used to add bulk to the ridge for improved

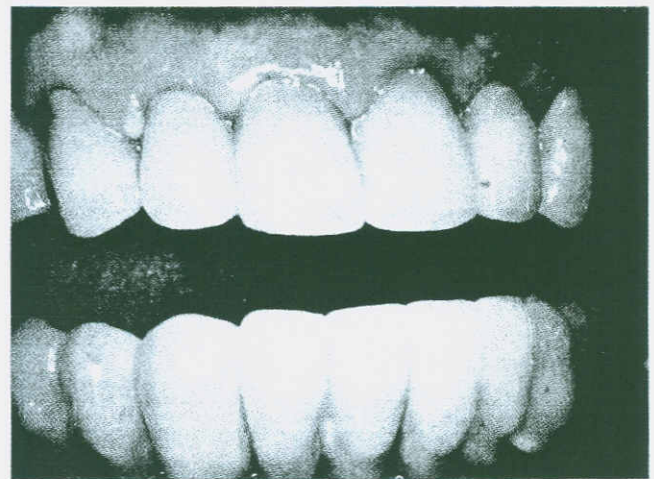


Figure 6a. Completed implant-supported maxillary and mandibular porcelain-to-metal prostheses.

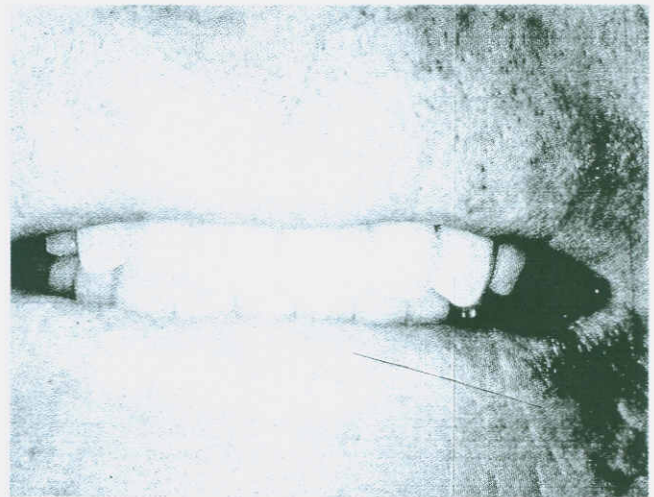


Figure 6b. Natural appearance of completed case.

pontic adaptation and to create a barrier of ceramic HA particles in a fibrous matrix which was planned to inhibit epithelial invagination (Wagner, 1989, 1990; Lemons, 1985).

The technique described for sinus floor elevation by the "green-stick fracture" method was reported by Linkow, Feigel, and others many years ago and has proven to be effective (Linkow, 1979; Feigel, 1989) (Fig. 5b). However, the introduction of resorbable RHA by grouting the implant vents and osteotomy prior to implant placement can enhance the potential for bone in-growth in the sinus floor subperiosteally and provide greater bone density at the implant-host interface.

Of the 63 sinus floors elevated and augmented by this method, two failures occurred. The failures

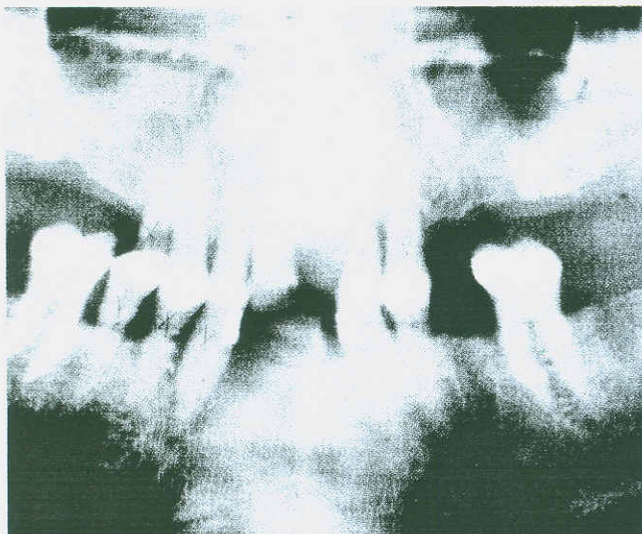


Figure 7. Case 2. Pre-operative panoramic radiograph.

were attributed to premature loading of the implants by provisional prostheses, such as treatment partials or dentures, coming into contact with the healing heads of the implants during the healing period. Both cases were re-done successfully after the implants were removed, the sites curretted and re-grafted with resorbable HA, and the implant placement procedure repeated several months later.

It is imperative that patients understand the importance of the passive healing of the graft and implant and that they be instructed to remove the provisional appliance immediately if irritation is noted around the implant's healing collar. The mandibular implants of Case 1 have been in function for four years and the maxillary sinus implants for 3½ years. Clinical and radiographic follow-up every six months revealed maintenance of healthy dense bone around all of the implants without any signs of saucerization at the implant abutments. Periodontal health was excellent, with probing depths varying between 0.5 and 1 mm around the four maxillary and six mandibular percutaneous abutment cervices.

Case 2

The patient, a sixty-three-year-old retired ship's captain, expressed a desire for full-mouth reconstruction and dental implants. He had found it extremely difficult to tolerate removable prostheses in the past. Clinical and radiographic examination and evaluation indicated dental implants and fixed prostheses to be a reasonable and predictable method of meeting this patient's needs (Fig. 7).

With the exception of mild but controlled hypertension, examination revealed an unremarkable medical history.

Treatment plan

After careful review of clinical observations, diagnostic casts, panoramic, periapical, and occlusal radiographs, a treatment plan was devised to treat both the maxillary and the mandibular arches with a combination of root-form and blade implants, with some of the remaining natural teeth to provide sufficient abutments for full-arch, fixed porcelain veneer bridges.

The maxillary first premolars, left canine, and retained roots of the left first molar were to be removed, with only the three remaining right anterior teeth being retained. The right canine would require endodontic therapy prior to commencement of the surgical phase of treatment. The left maxillary sinus floor would be elevated with sub-antral augmentation utilizing a resorbable hydroxylapatite graft placed through a lateral window approach since there was insufficient bone depth to accommodate an implant of sufficient size to support the prosthesis. When the antral floor was elevated and augmented, a double-abutted, submersible, grid-design blade implant (Ultimat-ics), 30 mm long and 14 mm deep, could be placed. The right posterior area would receive the same type of blade implant, slightly modified, with the conservative sinus floor elevation technique as described in Case 1. A 4.5-mm-diameter, 17-mm-long Core-Vent (Van Nuys, CA) root-form implant would be placed in the extraction site of the left canine tooth. All of the extractions, implant placements, and grafts would be performed in a single surgical appointment under local anesthesia and conscious sedation in the dental office. A temporary-treatment partial would be placed and worn during a four-month healing period prior to placement of abutments and completion of the prosthetic reconstruction.

Sinus lift surgery; Lateral approach. Case 2

The patient was pre-medicated with 2 mg of lorazepam (Ativan) the evening prior to scheduled surgery and given 1 mg 45 min pre-operatively. Prophylactic antibiotic and antihistamine therapy was started one day pre-operatively. Conscious sedation was augmented with 75 mg of meperidine, administered I.M. at the time of the surgery. Eight milligrams of dexamethasone was injected as well. The patient was prepared, draped, and anesthetized in the usual manner. Local anesthesia was administered with bupivacaine, 1:50,000 epinephrine.

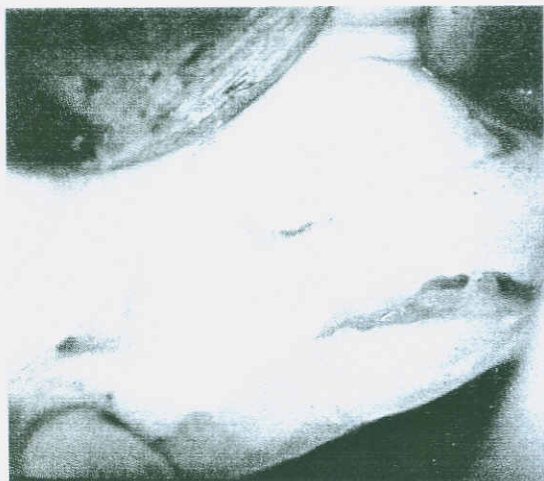


Figure 8a. Lateral aspect of the maxilla showing mesial and inferior borders of sinus opening scored through very thin cortical bone to periosteum of Schneiderian membrane.

Crestal incisions were made from the distal area of the maxillary tuberosity to the midline on the left and to the distal area of the canine tooth on the right, with a vertical relief incision labially in the anterior. Full-thickness mucoperiosteal flaps were elevated and retracted to expose the entire left and right maxillary alveolar ridges from the canines to the distal area of the tuberosities. The left buccal flap was retracted to expose the lateral aspect of the maxillae and zygomatic process and sutured to the buccal mucosa with three 3/0 black silk sutures so that access to the surgical site could be maintained.

A straight horizontal line parallel to the alveolar crest, 20 mm in length, was scribed onto the lateral wall of the left sinus approximately 10–12 mm superior to the alveolar crest by carefully brushing the thin cortical plate covering the sinus with a long-shank FG #4 round carbide bur at high speed and under profuse irrigation to outline the inferior border of the antral window. Vertical cuts, 10 mm long, in a superior direction, were made 90° to each end of the horizontal inferior border of the rectangular window in the same manner to form the mesial and distal ends of the rectangular opening (Fig. 8a). The handpiece was held with the long axis of the long shank bur nearly parallel to the lateral surface of the sinus wall, creating a self-limiting depth control of the cutting instrument by allowing only one-half of the bur's diameter to cut into the thin cortical bone. With the shank of the bur resting on the vertical surface of the alveolar ridge and the handpiece head held perpendicular to the ridge crest, with the handpiece

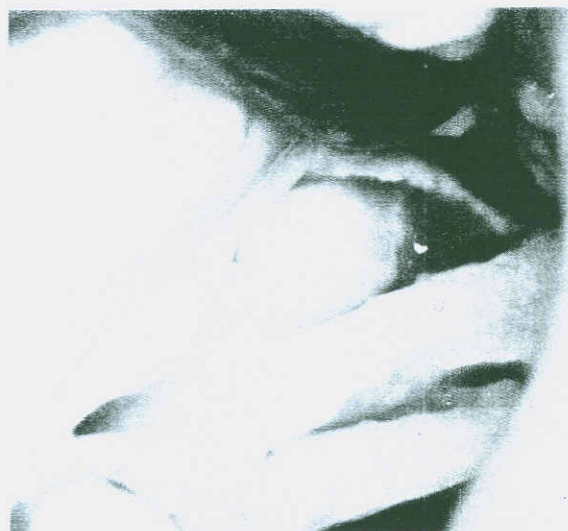

Figure 8b. A lateral window elevated to a horizontal position with sinus membrane attached, carefully stripped from antral floor, and elevated to form a lower chamber as graft receptor site.

rocking slightly in a palatal or buccal direction, the depth of the cut was controlled precisely to cut only through the bone and avoid engagement and laceration of the sinus membrane (Fig. 8b).

The superior border of the rectangular opening to the sinus was left intact without the cortical bone being scribed. This allowed it to serve as a hinge as the window was folded medially by being gently tapped with a blunt instrument along its inferior border. With the sinus membrane firmly attached to the medial surface of the cortical plate being folded into the sinus cavity, the Schneiderian membrane was elevated in a tent-like fashion as the window was pivoted medially and superiorly. The delicate membrane was teased away carefully from the sinus floor with curettes, inferior, mesial, and distal to the opening created, until the window became folded to a horizontal plane (Fig. 8c). The periosteum was stripped from all surfaces of the interior walls of the antrum below the superior border of the opening, and tucked above the roof of the newly formed augmentation site (Fig. 9).

An osteotomy, three centimeters in length, at the crest of the left alveolar ridge was prepared by use of Perimatix internally irrigated circular bone saws (Fig. 10) in a low-speed (300–400 RPM) R.A., high-torque handpiece (Fig. 11) and 700XL surgical burs in the teased manner described in Case 1. The osteotomy extended from the maxillary tuberosity to a point 10 mm distal to the canine, perpendicular to the sinus floor and ridge crest. The osteotomy penetrated through the cortical plate

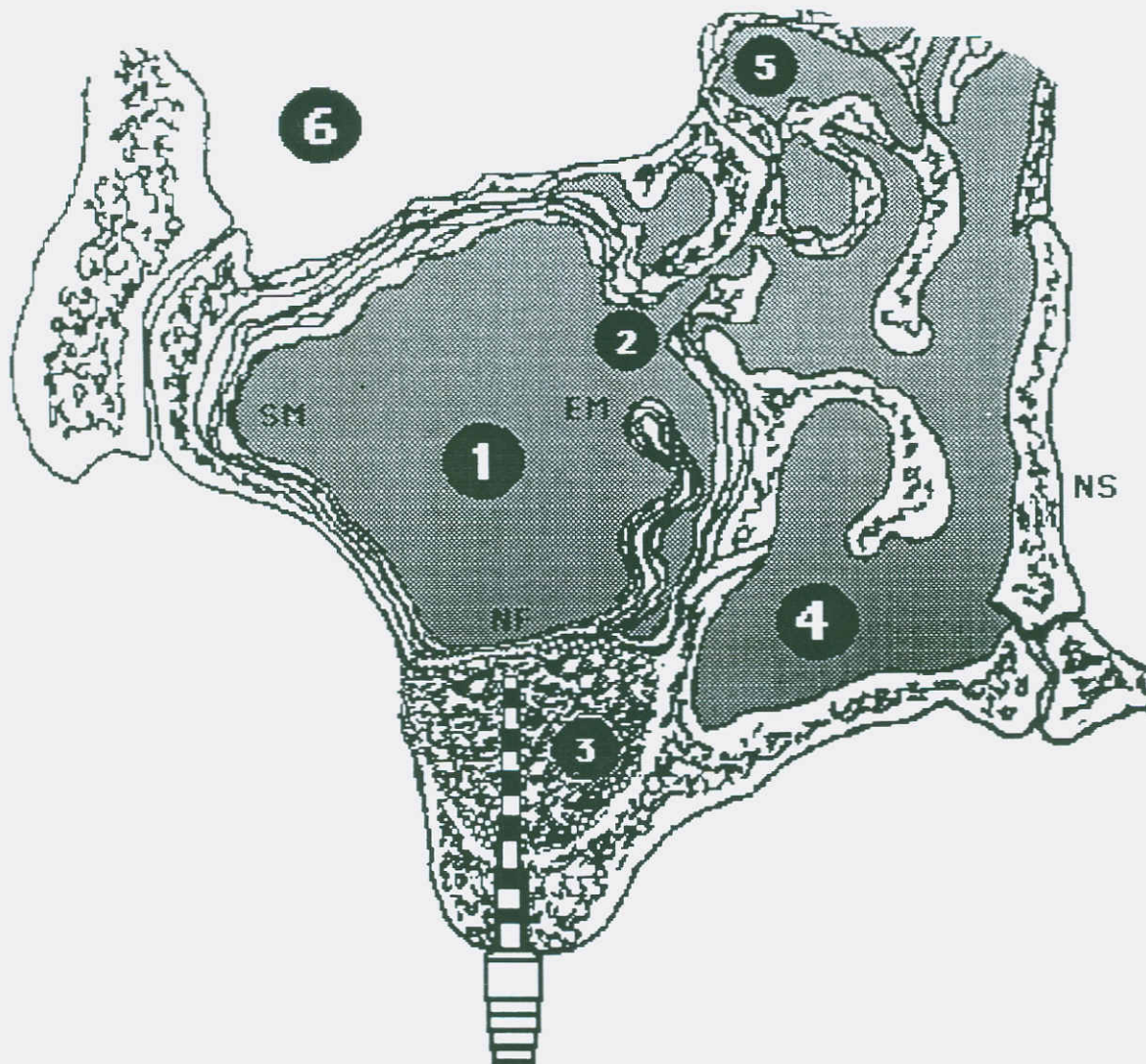


Figure 9. (1) Maxillary sinus, (2) ostium, (3) sub-antral augmentation, (4) nasal fossa, (5) ethmoidal cells, and (6) orbit. SM, Schneiderian membrane. NS, nasal septum. NF, new floor of sinus, and EM, elevated membrane. Labeled diagram showing cross-section of lateral-approach sinus floor elevation and sub-antral augmentation with a titanium blade implant seated within the augmented inferior chamber of the sinus.

of the antral floor extending mesially into the pre-sinus area and distally into the maxillary tuberosity where each end of the 30-mm-long implant was anchored firmly in bone when seated 2 mm below the crest of the ridge. Only the middle portion of the implant, approximately 20 to 22 mm in length, occupied the sinus cavity (Fig. 12).

A five-gram quantity of resorbable hydroxylapatite (OsteoGen) was mixed with the patient's freshly drawn venous blood, Avitene, and 125 mg of tetracycline into a thick-putty consistency (Fig. 13). The newly created host chamber was filled with the graft material prior to the final seating of the implant. All open vents of the blade implant were

grouted with the RHA mixture, and the implant was seated 2 mm beneath the crest of the alveolar ridge and projecting through the antral floor. The remainder of the sinus chamber lateral to the implant was filled to close the 20-x-10-mm opening in the lateral sinus wall completely. Frequent irrigation and lavage of the surgical sites with sterile, normal saline were performed throughout the procedure so that tissue hydration could be maintained. A 4.5-x-16-mm Core-Vent implant was placed in the alveolus of the extracted left canine, and a conservative sinus elevation (as described in Case 1) was performed contralaterally. The RHA coagulum was then placed in the osteotomies cov-

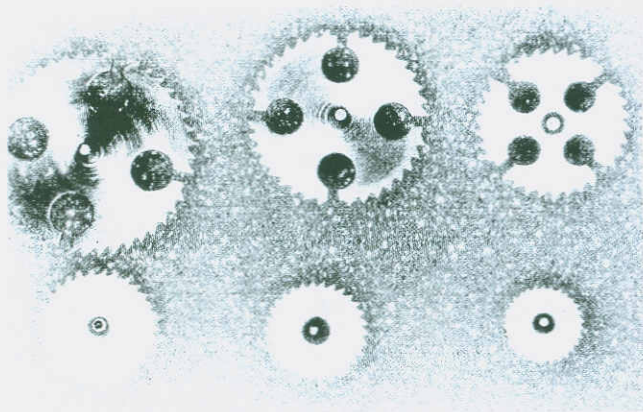


Figure 10. Perimatix circular bone saws for cutting osteotomy in fragile alveolar crest for blade implant placement. Perfectly smooth borders of the osteotomy were created with the saw to allow for a precision fit.

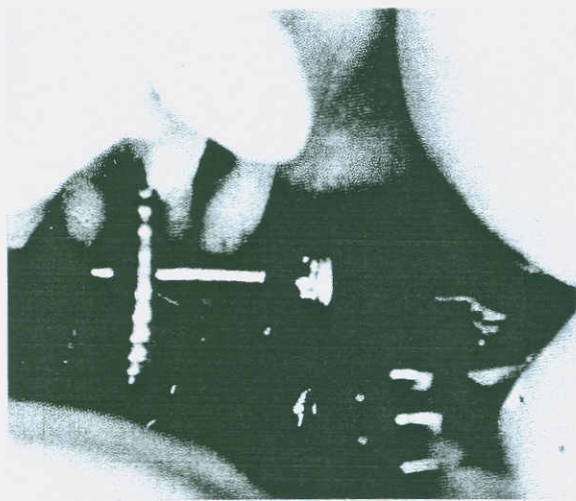


Figure 11. Circular saw in low-speed, high-torque RA handpiece and internal irrigation.

ering the shoulder of the seated blade and Core-Vent implants. The four prosthetic implant abutments were replaced with low-profile healing heads (bilaterally), and a nylon healing plug was placed in the root-form implant. The entire facial and crestal ridge was overlaid with an additional mixture of non-resorbable hydroxylapatite putty to provide more bulk to the residual ridge for pontic placement and to help reinforce the implants against occlusal pressures during mastication (Wagner, 1989, 1990) (Fig. 14). Mucoperiosteal flap borders were coapted and closure made with 3/0 chromic gut mattress and continuous sutures. After a period of four months, the submerged implant crevices were exposed surgically, abutments affixed, and the prosthetic phases completed by fab-

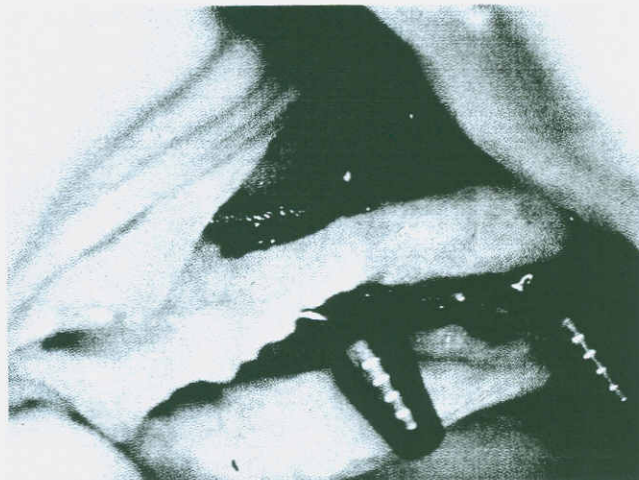

Figure 12. Blade implant 2 mm from final seated position extending into sinus graft site.

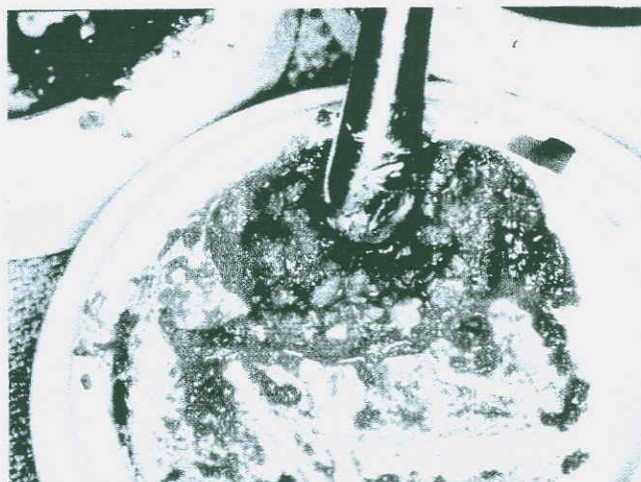


Figure 13. Resorbable HA OsteoGen being prepared with Avitene and autogenous venous blood. Graft is placed immediately after clotting occurs.

rication of a full-arch porcelain veneer bridge (Figs. 15-18).

After 3½ years, the implants are extremely rigid, yielding a distinct ring to percussion. Soft tissue is healthy, with sulcus depths measuring from 0.5 mm to 1 mm around the implant abutment cervices.

Discussion: Case 2

Over the past 4½ years, 32 sinus augmentations were performed with a resorbable hydroxylapatite, OsteoGen®, by utilizing the lateral window approach. All of these cases were of the type that possessed sufficient bone mesial and distal to the sinus so that at least 40% of the implants' surface

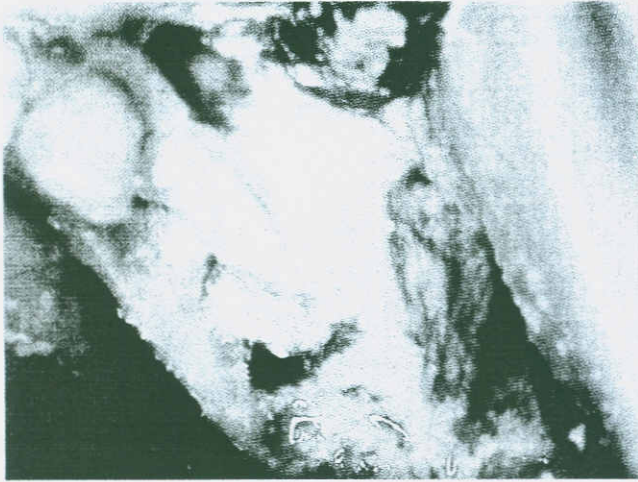

Figure 14. Graft site filled and ready for closure of mucoperiosteal flap.

areas could be placed in solid bone for immediate stabilization with grafts, as described in case #2. When this situation presents, the implant can be placed during the same surgery as the sinus elevation and graft and allowed to osseointegrate as the graft matures and ossifies. In cases where inadequate bone is present to stabilize the implant at its mesial and distal ends, only the sinus elevation and augmentation can be done, with the

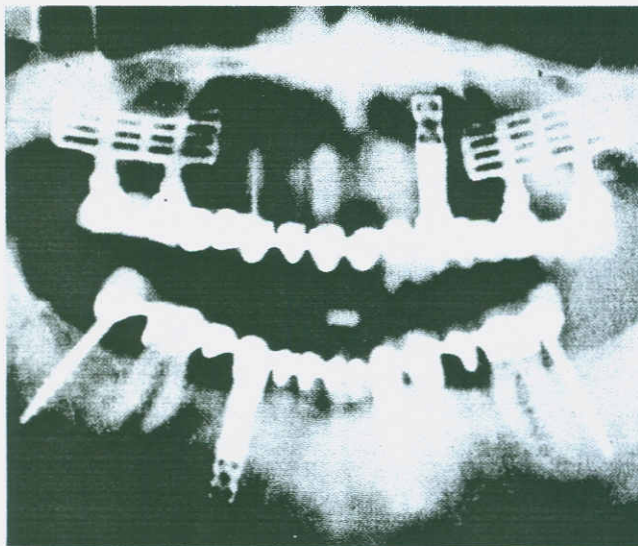


Figure 15. Case 2. Three-year post-operative panoramic view showing conservative sinus lift on the right side and a lateral approach sinus augmentation on the left with 4.5-mm Core-Vent implant at left canine site. The mandible was restored by use of two Core-Vent implants and two titanium bicortical screw implants bilaterally, along with natural 1st molars and the left 1st premolar to support a full-arch porcelain-veneer fixed prosthesis.

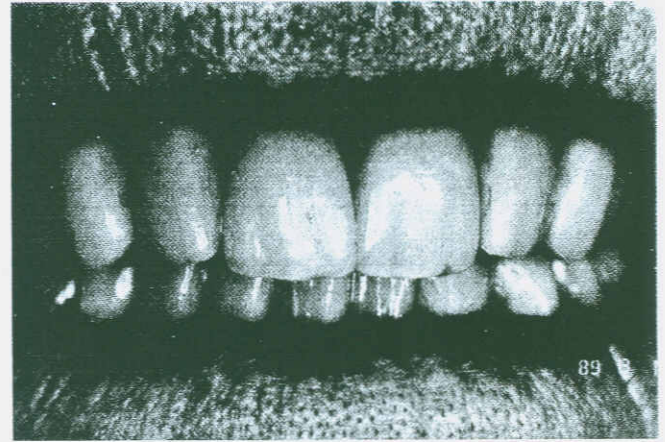


Figure 16. Close-up view of finished prostheses.

implant placement postponed for several months until adequate ossification of the graft has occurred (Lemons, 1985).

When cases are limited to these parameters—a somewhat more conservative approach than the two-stage surgery required on the larger, more invasive, sinuses—implant stability can be achieved much earlier and prosthetic reconstruction accomplished over a shorter period of time.

To date, all 32 cases have been successful, with complications occurring in three cases. All three of these cases involved post-operative infections which were treated with antibiotic, antihistamine, and decongestant therapy.

When a high-speed turbine handpiece is used close to delicate soft tissues, the direction in which the handpiece is directed is very important. For the same reason, sub-gingival cutting of crown margins during preparation should always be done by circumscribing the tooth in only a counterclockwise direction. The cutting flutes of the bur, rotating at 200,000+ RPM, behave much like the vanes of a rotary fan, creating a draft or vacuum depending on the direction of the cutting movement. If the direction is clockwise, soft tissue adjacent to the cut is drawn into the rapidly rotating cutting instrument, resulting in laceration. Conversely, if the direction of the cut is made counterclockwise, and the soft tissue is deflected away from the bur, damage to delicate structures can be avoided or minimized.

Discussion

The sub-antral augmentation procedure has been performed with a variety of graft materials, ranging from autogenous iliac crest grafts to various combinations of allografts and alloplastic materials, with satisfactory results reported by many

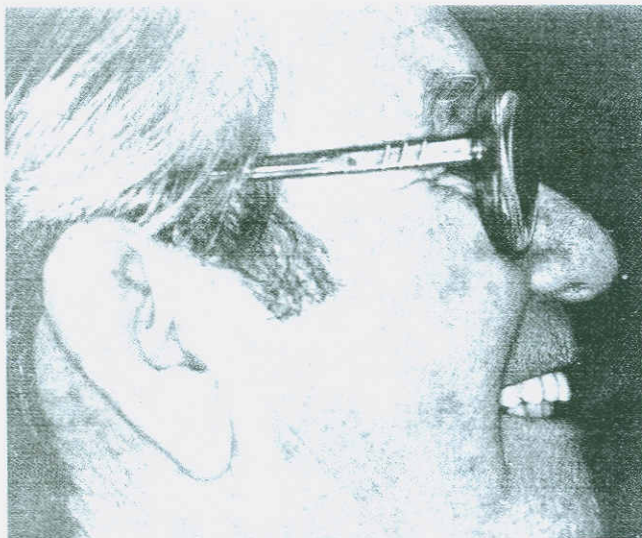


Figure 17. Esthetic and natural appearance of profile view of finished case.

researchers and clinicians (Chanavaz, 1990; McKinney and Lemons, 1985; Roberts *et al.*, 1988; Roberts, 1988; Whittaker *et al.*, 1989). This author, having experienced excellent results using the resorbable hydroxylapatite, microfibrillar collagen, and venous blood mixture in other implant surgical procedures, has achieved equally satisfactory results, from a clinical viewpoint, in utilizing the same mixture for sinus floor elevation and sub-antral augmentation.

Conclusion

OsteoGen® (HA Resorb)® is a resorbable, non-sintered, non-ceramic hydroxylapatite that is extremely biocompatible with both hard and soft tissues. When in direct contact with bone, there is little if any intervening soft tissue (LeGeros, 1988; Spivak *et al.*, 1990; Whittaker *et al.*, 1989). When the material is cut with rotary instruments after a few months of healing, its consistency is much like that of natural bone. Radiographically, it appears to be homogeneous with the natural substrate bone (Judy, 1986; Spivak *et al.*, 1990). OsteoGen® (HA Resorb)® serves two primary purposes: (1) It provides an important raw material that the body needs to create new bone; and (2) it provides a matrix or scaffold upon which the body can deposit that new bone. Since OsteoGen® is a highly micro-porous, non-sintered bone-grafting material with a predictable, controlled resorption rate, behaving like a "mineral reservoir" and inducing new bone formation *via* osteoconductive mechanisms, it appears to possess many of the qualities of an ideal bone-grafting material. Due



Figure 18. Through the utilization of advanced implant surgical techniques and technological advances, the patient was restored to an esthetically pleasing and natural appearance.

to the excellent results obtained with resorbable hydroxylapatite used in other regions of the mouth for various implant applications, the author used the same alloplastic graft mixture for sinus augmentation without the addition of any other allograft or alloplastic material.

References

- BROWN, W.E.; EIDELMAN, N.; and TOMAZIC, B. (1987): Octacalcium Phosphate as a Precursor in Biomineral Formation, *Adv Dent Res* 1:306-313.
- CHANAVAZ, M. (1990): Maxillary Sinus: Anatomy, Physiology, Surgery, and Bone Grafting Related to Implantology—Eleven Years of Surgical Experience (1979-1990), *J Oral Implantol* XVI: 199-209.
- CRANIN, A.N.; TOBIN, G.P.; and GELBMAN, J. (1987): Applications of Hydroxylapatite in Oral and Maxillofacial Surgery, Part II: Ridge Augmentation & Repair of Major Oral Defects, *Compend Contin Ed Dent* 8:334-345.
- dePUTTER, C.; de GROOT, J.; and SILLEVIS-SMITT, P.A.E. (1983): Transmucosal Implants of Dense Hydroxylapatite, *J Prosthet Dent* 49:87-95.
- FEIGEL, A. (1989): The Significance of Sinus Elevation for Blade Implantology—Report of an Autopsy Case, *J Oral Implantol* XV:237-248.
- HUBBARD, W. (1974): *Physiological Calcium Phosphate as an Orthopedic Implant Material*, PhD. Thesis, Marquette University.

- JARCHO, M.; KAY, J.F.; DROBECK, H.P.; and DOREMUS, R.H. (1976): Hydroxylapatite Interface, *J Bioeng* 1:79-92.
- JUDY, K. (1986): Oral Implantology Case Reports, *NY Dent J* 52:24-26.
- LeGEROS, R.Z. (1988): Calcium Phosphate Materials in Restorative Dentistry: A Review, *Adv Dent Res* 2:164-180.
- LEMONS, J.E. (1985): *Quantitative Characterization and Performance of Porous Implants for Hard Tissue Applications*, ASTM STP 859, Philadelphia.
- LINKOW, L.I. (1979): **Maxillary and Mandibular Implants, a Dynamic Approach to Oral Implantology**. New Haven, CT: Glarus Pub. Co., pp. 148-298.
- LINKOW, L.I. (1986): Bone Transplants Using the Symphysis, the Iliac Crest and Synthetic Bone Materials, *J Oral Implantol* 11:211-217.
- McKINNEY, R.V., Jr., and LEMONS, J.E. (1985): **The Dental Implant, Clinical and Biological Response of Oral Tissues**. Littleton, MA: PSG.
- MISCH, C. (1987): Maxillary Sinus Augmentation for Endosteal Implants, *Int J Oral Implantol* 4:49-57.
- ROBERTS, E. (1988): Bone Tissue Interface, abstract presented to the NIDR Implant Consensus Development Conference, June 13-18, Bethesda, MD.
- ROBERTS, E.W.; SMITH, R.K.; ZILBERMAN, V.; MOZARY, P.G.; and SMITH, R.S. (1988): Osseous Adaptation to Continuous Load of Rigid Endosseous Implants, *Orale Implantologie (DGZI)* 14:30-42.
- SPIVAK, J.M.; RICCI, J.L.; BLUMENTHAL, N.C.; and ALEXANDER, H. (1990): A New Canine Model to Evaluate the Biological Response of Intramedullary Bone to Implant Materials and Surfaces, *J Biomed Mater Res* 24:1121-1149.
- WAGNER, J.R. (1988): A Rapid and Precise Subperiosteal Impression Technique for Today's Highly Evolved Mandibular Subperiosteal Implants, *J Oral Implantol* XIV: 485-509.
- WAGNER, J.R. (1989): A Clinical and Histological Case Study using Resorbable Hydroxylapatite for the Repair of Osseous Defects prior to Endosseous Implant Surgery, *J Oral Implantol* XV:186-192.
- WAGNER, J.R. (1990): A New Osteoconductive Resorbable Hydroxylapatite Graft Material that Restores Bony Defects with Viable Bone, *J FL Dent Assoc* 2:4C-5C.
- WHITTAKER, J.M.; JAMES, R.A.; LOZADA, J.; CORDOVA, C.; and GaREY, D. (1989): Histological Response and Clinical Evaluation of Heterograft and Allograft Materials in the Elevation of the Maxillary Sinus for the Preparation of Endosteal Dental Implant Sites. Simultaneous Sinus Elevation and Root Form Implantation; An Eight-month Autopsy Report, *J Oral Implantol* XV:141-144.
- WICHER, W. (1975): Clinical Applications of a New Topical Hemostat in Various Surgical Procedures. In: **Proceedings, Symposium on Avitene®** (microfibrillar collagen hemostat), San Francisco, CA.

Dr. Wagner is in private practice at 7100 Plantation Road, Suite 9, Pensacola, FL 32504.